



## INTERNATIONAL JOURNAL OF PAEDIATRICS AND GERIATRICS

P-ISSN: 2664-3685

E-ISSN: 2664-3693

[www.paediatricjournal.com](http://www.paediatricjournal.com)

IJPG 2020; 3(1): 141-148

Received: 08-12-2019

Accepted: 07-01-2020

**Dr. R Fedal**

Département of Pediatric Surgery Nefissa Hamoud Teaching Hospital Algiers, Algeria.

**Pr. T Boudiaf**

Département of Pediatric Surgery Nefissa Hamoud Teaching Hospital Algiers, Algeria.

**Dr. R Khiali**

Département of General Surgery EPH Ain Taya, Algiers.

**Dr. S Ammari**

Département of General Surgery EPH Ain Taya, Algiers.

**Pr. M Taieb**

Département of General Surgery EPH Ain Taya, Algiers.

**Dr. N Nait Slimane**

Département of General Surgery EPH Ain Taya, Algiers.

**A.B Endjaballah**

MD Ph.D. FACS, Département of General Surgery EPH Ain Taya, Algiers.

**Corresponding Author:**

**A.B Endjaballah**

MD Ph.D. FACS, Département of General Surgery EPH Ain Taya, Algiers.

## Choledochal cyst: A Common cause of cholangitis in Pediatrics

**Dr. R Fedala, Pr. T Boudiaf, Dr. R Khiali, Dr. S Ammari, Pr. M Taieb, Dr. N Nait Slimane and A.B Endjaballah**

**DOI:** <https://doi.org/10.33545/26643685.2020.v3.i1c.71>

### Abstract

Choledochal cysts (CC) are a congenital cystic dilation of the extrahepatic and/or intrahepatic bile ducts that approximately 80% of the patients are diagnosed in childhood. Despite the diversity of etiologies, the main elements of the predominantly types I and IV, which constitute the majority of all types, have become clearer. The clinical presentation varies from jaundice in young patients to non-specific abdominal pain in older patients, but morbidity increases with complications such as angiocholitis, pancreatitis, perforation, hepatitis, liver failure and malignancy in late-diagnosed patients. MRCP is considered the gold standard diagnostic tool today, capable of accurately assessing biliary anatomy. The therapeutic approach has progressed over the years. It is based on the removal of the entire cyst and reconstruction of the remaining bile ducts up to drainage.

**Keywords:** Choledochal cyst, pediatric population, surgical treatment, Common bile duct

### Introduction

Choledochal cyst, also known as Cystic dilatation of the common bile duct (characterized by disproportionate dilatation of the biliary ductal system)<sup>[1]</sup>. It was first described by Vater and Ezler in 1723, Douglas published the first complete clinical description of the anomaly in a patient in 1853. He speculated about the congenital nature of this anomaly. In 1959, Alonso-Lej *et al.* Published an extensive review of 94 cases in the literature and added two cases of their own<sup>[2]</sup>. They classified choledochal cysts into three types. In 1977, Todani *et al.* Further classified this anomaly into five types<sup>[3]</sup>. Subsequent subtypes based on cholangiographic findings have been described.

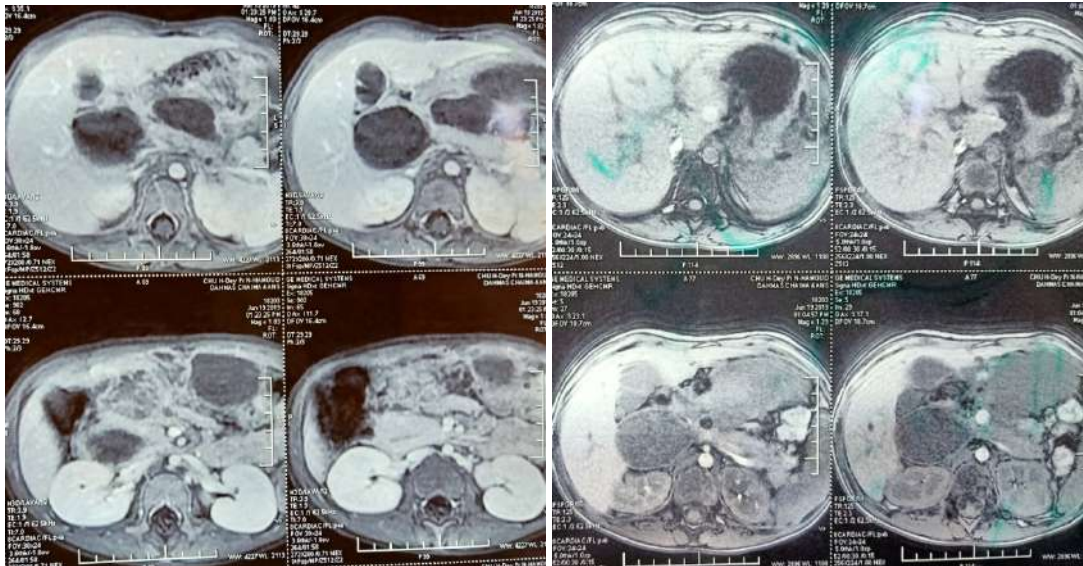
It is estimated that the overall incidence is one in every 150,000 live births, with a female predominance of 4:1<sup>[4]</sup>. They may manifest only in adulthood, but about 60% of cases are diagnosed in the first decade of life<sup>[5]</sup>. There are several etiological hypotheses, but the most accepted is Babbitt's theory, which attributes the formation of cysts to an anomaly at the junction of the pancreatic duct with the common bile duct, outside the Vater's ampulla, resulting in a long common duct, which allows the reflux of pancreatic secretion in to the biliary common duct. Patients with extensive dilatations of the biliary tract have a predisposition to biliary stasis, leading to recurrent cholangitis, calculus formation and, ultimately, secondary biliary cirrhosis and malign transformation<sup>[6]</sup>. The earliest reported choledochal cyst was detected in a fetus at 15 weeks' gestation, which may correspond to the timing of the formation of pancreatic enzymes<sup>[7]</sup>. Fetal development should be carefully monitored with serial ultrasonography after such a discovery. Most centers prefer to excise the cyst shortly after birth. A waiting period of a few weeks is necessary to stabilize the baby and allow for proper preoperative evaluation<sup>[8]</sup>. The active pancreatic enzymes provoke inflammation and weakness of the walls of the bile duct, leading to the formation of the cysts. Complete cyst excision is the best treatment strategy and involves complete resection of the cyst associated with bile duct reconstruction<sup>[9]</sup>. The management of choledochal cysts has evolved during the past several decades. Complete excision of the cyst and biliary bypass have become the treatment of choice<sup>[10]</sup>. From the first report, by Farello *et al.*<sup>[11]</sup>. In 1995, laparoscopic excision of cysts with Roux-en-Y and hepaticojejunal anastomosis reconstruction in children has gained worldwide attention<sup>[12]</sup>.

**Case report**

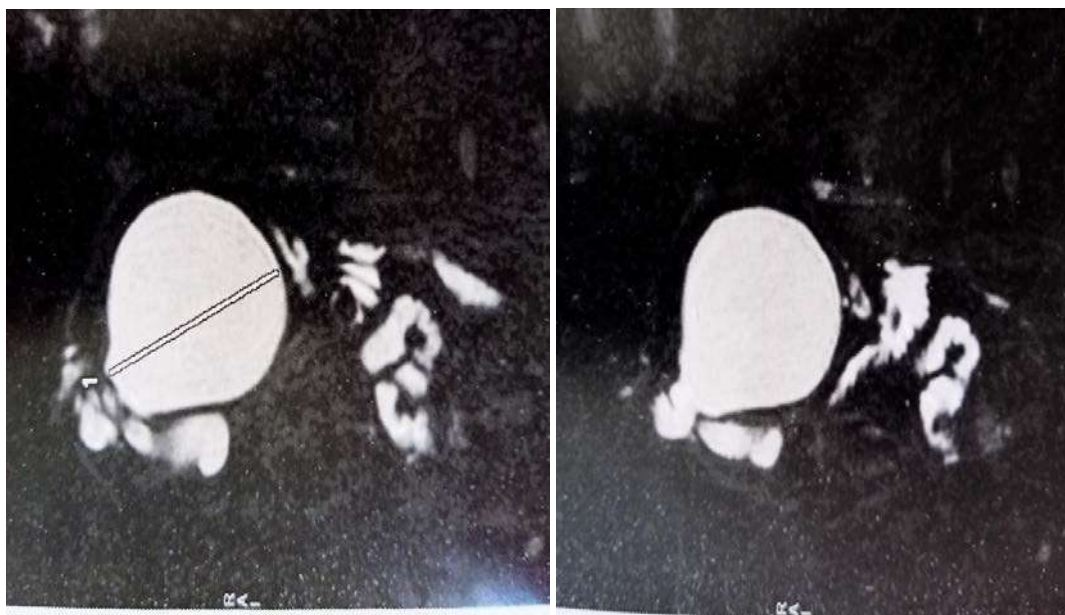
A 05-year-old female patient with history of recurrent cholangitis admitted for the first time for acute cholangitis evolving for three days with jaundice. The choledochal cyst was diagnosed 7 months ago during an assessment for exploration of repeated cholangitis. on admission there is a clinical and biological cholestatic syndrome with jaundice and the total bilirubin level = 15mg/ml -- GGT=100UI/L -- PAL = 251.6UI/L. Abdominal ultrasonography showed: alithiasic curved gall bladder with oblong cystic formation in projection of the hepatic pedicle measuring 62mm x 59mm x 49mm with echogenic content communicating with the bile ducts which are slightly dilated. A bili-MRI was

performed and revealed a cystic dilatation of the bile duct without obstacle Todani type Ia associated with a Wirsung canal microlithiasis with dilatation of the cephalic portion of the head (Figure 1, 2, 3 et 4).

The patient was operated on, after improvement of her clinical condition and resolution of jaundice and normalization of liver function tests. She underwent cholecystectomy with resection of the bile duct cyst with hepatic-jejunal anastomosis using the Roux on Y technique. She passed a smooth post operative period and was discharged on the 6 th post-operative day She was followed on OPD for six months without any hepatico-biliary symptoms.



**Fig 1, 2:** Showing choledochal Cyst type Ia of Todani



**Fig 3, 4:** Showing choledochal Cyst type Ia of Todani

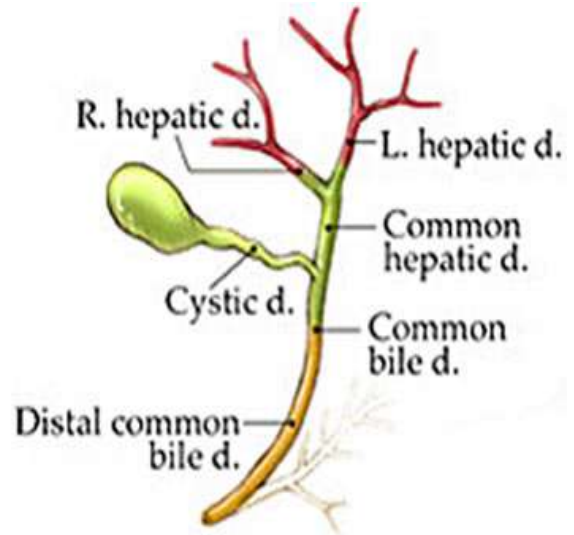
**Discussion**

Congenital biliary dilatation constitutes a diagnostic and therapeutic challenge for pediatric surgeons, requiring a high level of suspicion and an effective etiological investigation for accurate diagnosis and adequate treatment [5]. Approximately 80% of patients have developed symptoms in childhood [13] and the most frequent symptoms

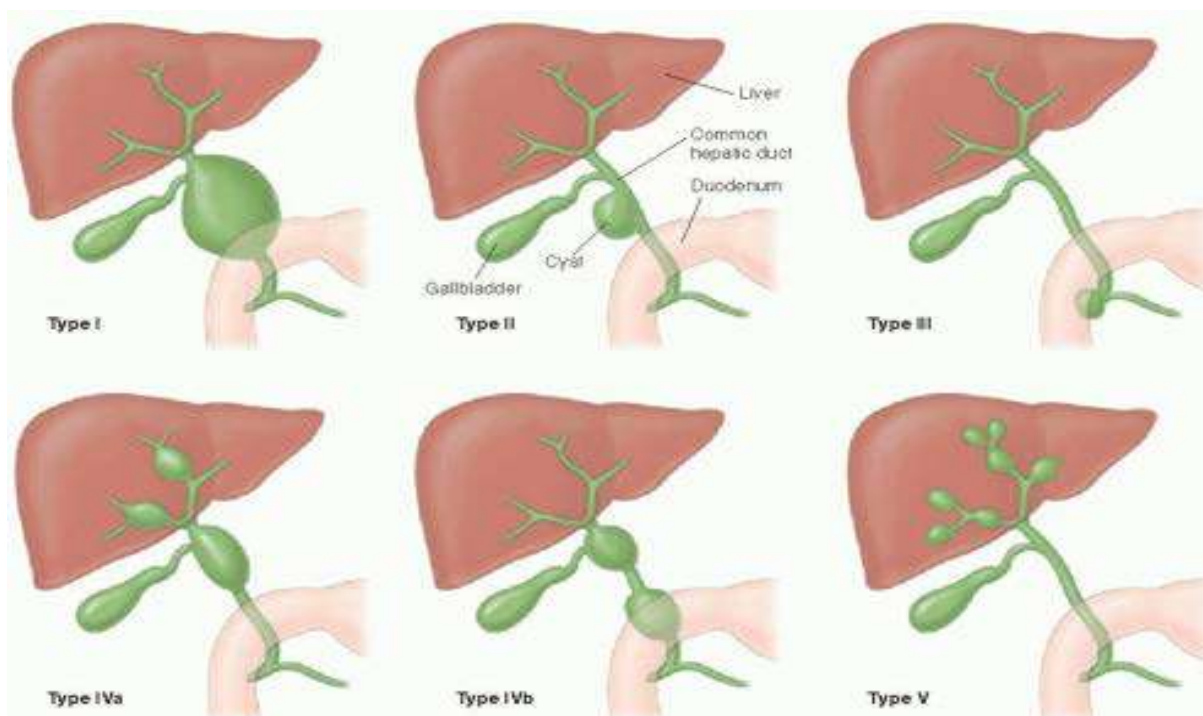
are abdominal pain in about 60% of cases, jaundice in 80% of cases, and vomiting in about 44% of cases [9]. Its etiology is not well defined, the most commonly accepted etiological theory is that of Babbitt DP 1969 [14] proposing that an abnormal junction between the biliopancreatic duct results in the formation of a common duct which causes reflux of pancreatic secretion into the biliary tract, causing increased



pressure and subsequent dilatation of the duct. Other authors have found this association in 96% of cases [15-18]. Further congenital abnormalities have been reported to be associated with Choledochal cyst such as double common bile duct, hepatic fibrosis, sclerosing cholangitis, pancreatic cyst, ring pancreas and cardiac abnormalities [19-21]. In addition, it is recognised that primary restrictions of VBP may also contribute to the development of Choledochal cyst. The types of Choledochal cyst are determined according to the location, severity and duration of the restriction. Pre-operative detection of these narrowings is important because treatment of Choledochal cyst without taking the narrowing into account can lead to recurrent episodes of cholangitis. This mechanism has been underestimated and is now thought to play a more important role in the pathophysiology of Choledochal cyst [22].



**Fig 5:** Anatomy of biliary tract



**Fig 6:** Todani Classification of Choledochal cysts:

- Type I, II and III = Extrahepatic
- Type IV = Extrahepatic + Intrahepatic
- Type V = Intrahepatic

**Classification:** Alonso-Lej first defined three types of biliary dilatations in 1959; this classification system has been widely accepted ever since. Todani has expanded this classification in 1977 and has subdivided the Choledochal cyst into five subgroups. Todani modified the classification

to include anomalies of the pancreatic junction, and the resulting system became the final and most widely used method of classification [23]. According to the Todani classification, Choledochal cyst are classified as follows:

|          |   |
|----------|---|
| Type IA  | Cystic dilatation of the extrahepatic bile ducts                          |
| Type IB  | Extrahepatic distal focal - segmental biliary dilatation                  |
| Type IC  | Extrahepatic fusiform biliary dilatation                                  |
| Type II  | Extrahepatic biliary diverticula  |
| Type III | Intraduodenal portion of the common bile duct dilatation (Choledocoele)   |
| Type VA  | Multiple cystic dilatation of the intrahepatic and extrahepatic bile duct |
| Type IVB | Multiple cystic dilatation of the only extrahepatic bile duct             |
| Type V   | Cystic dilatation of the intrahepatic bile ducts (Caroli's disease)       |

**Tableau 1:** Todani of classification

The classic triad of jaundice, abdominal pain and a palpable mass occurs in only 20% of patients, mainly in the pediatric age group [4]. The clinical outcome of CC is the secondary development of cholangitis and ascending pancreatitis, which occur due to biliary stasis, formation of gallstones, development of secondary inflammation [24, 25]. Pancreatitis develops due to obstruction of the secondary pancreatic duct by gallstones and protein-rich secretions from the dysplastic epithelium [26, 27]. The cause of recurrent cholangitis in patients with intrahepatic disease (types IVA and V) is bacterial colonization caused by gallstones and obstruction due to intrahepatic biliary stasis. The clinical presentation in these patients may progress to portal hypertension and secondary biliary cirrhosis. Portal hypertension may develop without cirrhosis because of the mechanical pressure of the cyst on the portal vein [28, 29]. Unfortunately, 29-62% of pediatric patients with CC have been diagnosed with choledocholithiasis [30, 31]. Which means that it can be difficult to distinguish between the two situations (CC-associated and non-CC-associated choledocholithiasis). Chedocholithiasis can also cause dilatation of VBP, which may be misdiagnosed as CC [32]. In 1-2% of cases, especially in infants, CC can present with rupture and biliary peritonitis requiring emergency biliary drainage [33, 34]. It is not surprising to diagnose pancreatitis in patients with CC due to the association of the presence of APBDU [35, 36].

At the present time, the survey begins with ultrasound, which is highly sensitive for the diagnosis of biliary tract diseases. Prenatal diagnosis has been described, in some cases, as early as 15 weeks of gestation and has become increasingly common in our environment [1]. Non-invasive tests to define the anatomy of the biliary tree include computerized tomography «CT scan» (sensitivity and specificity approximately 90%), technetium-99 hepato-biliary scintigraphy and magnetic resonance imaging (sensitivity 70-100% and specificity 90-100%). All of these methods can be used as a diagnostic approach, with magnetic resonance imaging being the gold standard [4, 5]. Scanning is not only necessary to demonstrate the continuity of the cyst with the biliary tree, but also to determine the relationship of the cyst with the surrounding structures and the presence of any associated malignancy. In order to adequately plan the operative strategy, CTscan cholangiography can be performed to identify the complete anatomy of the biliary tree, but unfortunately it is less sensitive to visualize the pancreatic duct which is responsible for the reflux of contrast into the bile ducts [37]. As it is well known now, the nephrohepatotoxicity of the contrast product and the exposure to ionized radiation are the restrictions on the use of the CT scanner in the pediatric population [38].

In addition, MRCP is the preferred modality in the paediatric population because of the invasive nature and inherent risks of endoscopic ultrasound and ERCP, despite their ability to detect the common ductal abnormality [39]. MRCP has also been shown to be as effective as intraoperative cholangiography in planning surgical strategy. In particular, the lower cost and morbidity compared to other imaging/diagnostic modalities, as well as the reliability of detection of Choledochal cyst associated abnormalities such as cholangiocarcinoma and choledocholithiasis, are some of the favourable features of MRCP [39, 40]. ERCP should only be performed in situations

where adequate diagnosis cannot be established by other less invasive tests, or where therapeutic performance (complications such as cholangitis or obstruction of gallstones [41, 42] and stabilization of patients with preparation for the next definitive surgical procedure) is necessary [43, 44].

In spite of a plethora of diagnostic methods, the dg can be difficult to determine several differential diagnoses have been identified. There are many diseases including biliary atresia, infectious hepatitis, embryonal hepatic rhabdomyosarcoma, biliary lithiasis, pancreatitis, biliary hamartoma in the differential diagnosis of Choledochal cyst, especially biliary atresia that is one of the two causes of neonatal obstructive jaundice in neonatal period [19]. Differentiating cystic biliary atresia, a subtype of biliary atresia and has an entirely different treatment approach, from Choledochal cyst is particularly difficult. Therefore, prompt accurate diagnosis is critical [45].

Treatment of choledochal cysts is surgical, except for type V multiple intrahepatic cysts, which can benefit from medical management for variable periods of time [46]. The treatment time of antenatal diagnosed of CCs has been still a matter of debate. Some reports say that they can be operated within 2-6 weeks, even if they are asymptomatic, due to a potential complication risk of cysts, whereas, the others suggest that they can be followed-up for a time of period with US and regular monitoring of liver functions [47, 48].

In the past, surgical suction and external drainage were used extensively because the vast majority of patients were quite ill and a simple and quick procedure was practical. These methods of external drainage of the biliary tree failed largely because of many complications, including recurrent angiocholitis and biliary fistulas. Mortality was high. Percutaneous drainage surgery can now be performed prior to definitive surgery in cases of severe and acute disease. This procedure is safe and generally well tolerated; however, it is not necessary in most patients [49-52]. The treatment of choice is a surgical procedure and consists of a total resection of the cyst followed by reconstruction with a bilio-digestive anastomosis. Laparoscopic procedure of choledochal cysts was described in 1995 [53] and confirmed that it could be carried out in children as young as 3 months [11] and as small as 6 kg [54]. Regarding the laparoscopic approach, the important advantages consist of excellent visualization (view) and lower blood loss [55] as well as enhanced postoperative recovery, a reduced amount of surgical trauma, fewer postoperative pain, less trauma to the abdominal wall, shorter drainage time of the abdominal cavity, reduction of postoperative paralytic ileus time and shorter hospital stay. General complications and mortality rates are also lower compared with the series of patients managed by open surgery [56, 12].

Several groups have successfully performed laparoscopic-assisted and laparoscopic total cyst excision with Roux-en-Y hepatoenterostomy with complication rates comparable to those of the open procedure [57] Li *et al.* Performed laparoscopic cyst excision with laparoscopic-assisted Roux-en-Y hepatoenterostomy in 35 children (33 cyst type, two fusiform) without conversion to the open procedure and with postoperative stays of 3-5 days [58-60]. The procedure is described in detail for both choledochal cyst and biliary atresia surgery by Martinez-Ferro *et al.* (2005). [61], Liuming *et al.* [55] and Liem *et al.* [56] also concluded that laparoscopic excision was as safe as open excision.

The surgical approach consists of the complete removal of the cyst associated with the reconstruction of the biliary tree through a bilioenteric anastomosis. Although hepaticojejunostomy has been considered the gold standard for many years, hepaticoduodenostomy has been gaining more and more adherents and has been preferred by many surgeons who claim shorter operative time, less chances of postoperative adhesions, shorter hospitalization time, lower incidence of anastomotic fistulas, and also greater ease of endoscopic dilatation in case of anastomosis stenosis [6].

Total excision of the cyst in types I, II, and IV followed by reconstruction of the biliary tree with hepaticojejunostomy in a Roux-en-Y approach has been commonly established as the procedure of choice in treating choledochal cysts and has been found to be greater to hepaticoduodenostomy. This method consists of excising distal CBD. As a result, it blocks the reflux of pancreatic enzymes into the bile ducts, thereby reducing the incidence of biliary tract carcinomas [52].

Biliary surgery can be performed with a Roux Y-hepaticojejunostomy as high as possible, near the hilum of the liver. Some authors, including Raffensperger and Shamberger, have interposed an inverted segment of the jejunum to prevent reflux. This idea has not been universally accepted [62, 63]. No stent is systematically necessary.

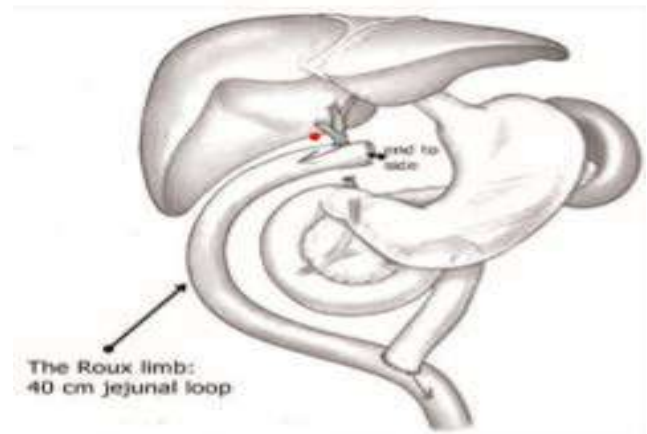
For choledochal cysts type II a simple excision of the diverticulum with ductoplasty for surgical repair of VBP is all that is needed. Laparoscopic excision has been performed successfully in this relatively infrequent disease [64, 65].

In choledochal cysts type III bile duct cysts, the general approach is a lateral duodenotomy with bile duct dissection to drain the bile duct and pancreatic duct directly into the duodenum. Both ducts must be carefully examined to determine if ductoplasty is required [66].

In patients with choledochal cysts type IV with intrahepatic cysts, each case is evaluated separately, and the criterion of adequate bile drainage is assessed. Excision of dilated extrahepatic bile ducts to the hepatic porta, with hepaticojejunostomy at the hilum, may permit good bile drainage and satisfactory decompression of intrahepatic cysts. If intrahepatic cysts are located in a small area of the liver, partial hepatectomy may be indicated [67, 68].

In the case of choledochal cysts type V, patients with localized disease may benefit from a liver lobectomy. If the illness is widespread, implicating both lobes of the liver, treatment is palliative and a liver transplant can be recommended [69]. Another controversial issue regarding treatment concerns the drainage of the abdominal cavity. Recent studies have demonstrated some aspects of drainage, such as severe infections and narrowing of the common hepatic duct [70].

Our patient was treated first for acute cholangitis and readmitted for the treatment of the choledochal cyst by resection of the cyst followed by hepaticojejunostomy Roux en Y (Figure 6). She passed a smooth post-operative period. She was discharged on the seventh post-operative day. She was seen in OPD three months later without any biliary & hepatic symptomatology.

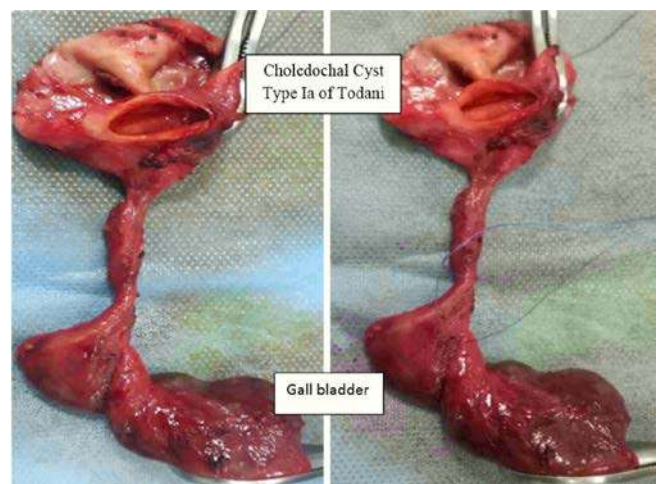


**Fig 7:** Hepatico-jejunostomy in a Roux-en-Y procedure

Post-operatively, patients must be monitored every 6 months for 3 years, then every year. At the first follow-up, all patients should be evaluated with a complete blood count, liver tests and abdominal ultrasound examination, but thereafter only symptomatic patients are examined. Long-term follow-up may include consultations, telephone conversations, and mail surveys in order to avoid the occurrence of complications occurring after hepaticojejunostomy on Roux Y such as biliary leak, cholangitis, anastomotic stenosis, surgical re-intervention and postoperative small bowel obstruction [71].

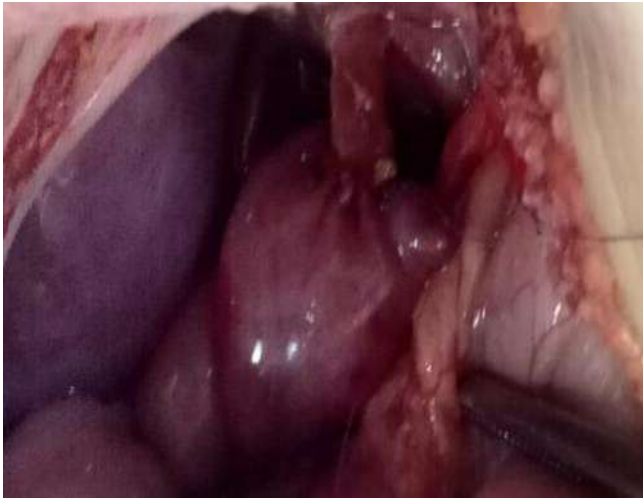
### Conclusion

Choledochal cyst is a rare condition for which surgery is well accepted (complete excision). However, the surgical technique for reconstruction of biliary ducts is not yet well defined. Up to now, observations show a slight advantage for Hepatico jejunal anastomosis in Roux en Y. On the other hand, since there are no prospective randomized clinical studies available, the choice of biliary tract reconstruction technique will be decided by the decision and experience of the surgeon treating the patient. All patients should be monitored for an extended period of time, regardless of the surgical technique performed.



**Fig 8 & 9:** Showing the surgical specimen including large choledochal cyst gallbladder and cystic duct





**Fig 10:** Showing accomplishment of a hepatico-jejunal anastomosis in Roux on Y

## References

- Subramony R, Kittisarapong N, Barata I, Nelson M. Choledochal cyst mimicking gallbladder with stones in a six-year-old with right-sided abdominal pain *West J Emerg Med.* 2015; 16(4):568-71.
- Alonso-Lej F, Rever WB Jr, Pessagno DJ. Congenital choledochal cyst, with a report of 2, and an analysis of 94, cases *Int Abstr Surg.* 1959; 108(1):1-30.
- Todani T, Watanabe Y, Narusue M *et al.* Congenital bile duct cysts: Classification, operative procedures, and review of thirty-seven cases including cancer arising from choledochal cyst *Am J Surg.* 1977; 134(2):263-9.
- Silva-Baez H, Coello-Ramírez P, Ixtabalán-Escalante EM, Sotelo-Anaya E, Gallo-Morales M, Cordero-Estrada E *et al.* Treatment of choledochal cyst in a pediatric population. A single institution experience of 15-years Case series *Ann Med Surg (Lond)* 2015; 5:81-5.
- Forny DN, Ferrante SM, Silveira VG, Siviero I, Chagas VL, Méio IB. Choledochal cyst in childhood: review of 30 cases *Rev Col Bras Cir.* 2014; 41(5):331-5
- Gezer HÖ, Oguzkurt P, Temiz A, Ince E, Ezer SS, Hiçsönmez A. Choledochal cyst in children: intrahepatic ductal dilatation does not indicate true intrahepatic biliary duct disease. *Turk J Gastroenterol.* 2016;27(1):23-9.
- Komuro H, Makino S, Tahara K. Choledochal cyst associated with duodenal obstruction. *J Pediatr Surg.* 2000 Aug. 35(8):1259-62.
- Netherlands Study Group for Choledochus Cysts/Malformations (NeSCHoC), van den Eijnden MHA, de Kleine RH, de Blaauw I, Peeters PMJG, Koot BGP, *et al.* The timing of surgery of antenatally diagnosed choledochal malformations: A descriptive analysis of 26-year nationwide cohort *J Pediatr Surg.* 2017 ; 52(7):1156-1160.
- Gadelhak N, Shehta A. Hamed H. Diagnosis and management of choledochal cyst: 20 years of single center experience *World J Gastroenterol.* 2014; 20(22):7061-6.
- Soares KC, Goldstein SD, Ghaseb MA, Kamel I, Hackam DJ, Pawlik TM. Pediatric choledochal cysts: diagnosis and current management. *Pediatr Surg Int.* 2017; 33 (6):637-650.
- Farello GA, Cerofolini A, Rebonato M, Bergamaschi G, Ferrari C, Chiappetta A. Congenital choledochal cyst: Video-guided laparoscopic treatment *Surg Laparosc Endosc.* 1995; 5(5):354-8.
- Lee JH, Kim SH, Kim HY, Choi YH, Jung SE, Park KW. Early experience of laparoscopic choledochal cyst excision in children *J Korean Surg Soc.* 2013; 85(5):225-9.
- Yurtutan N, Karakus SC, Koku N, Demirci M, Ucak R. A giant choledochal cyst in infancy: A case report *Korean J Pediatr.* 2016; 59(5):239-41.
- Babbitt D.P. Congenital choledochal cysts: new etiological concept based on anomalous relationships of the common bile duct and pancreatic bulb *Ann Radiol Paris.* 1969; 12:231-234.
- Katabi N, Pillarisetty V.G, DeMatteo R, Klimstra D.S. Choledochal cysts: A clinicopathologic study of 36 cases with emphasis on the morphologic and the immunohistochemical features of premalignant and malignant alterations *Hum Pathol.* 2014; 45(10):2107–2114.
- De Angelis P, Foschia F, Romeo E, Caldaro T, Rea F, Di Abriola G.F. Role of endoscopic retrograde cholangiopancreatography in diagnosis and management of congenital choledochal Cysts: 28 pediatric cases *J Pediatr Surg.* 2012; 47:885–888.
- Morine Y, Shimada M, Takamatsu H, Araida T, Endo I, Kubota M. Clinical features of pancreaticobiliary maljunction: Update analysis of 2nd Japan-nationwide survey *J Hepatobiliary Pancreat Sci.* 2013; 20:472-480.
- Todani T, Watanabe Y, Toki A, Sato Y, Ogura K, Yamamoto S. Surgical treatment of choledochal cyst in children *J Hepatobiliary Pancreat Surg* 1996; 3:417-422.
- Soares K.C, Arnaoutakis D.J. Kamel I, Rastegar N, Anders R, Maithel S. Choledochal cysts: presentation, clinical differentiation, and management *J Am Coll Surg.* 2014; 219(6):1167–1180.
- Murphy A.J, Axt J.R. III HNL. Associations between pediatric choledochal cysts, biliary atresia, and congenital cardiac anomalies *J Surg Res* 2012; 177(2):e59–e63
- Okada A, Higaki J, Nakamura T., Fukui Y., Kamata S. Pancreatitis associated with choledochal cyst and other anomalies in childhood *Br. J Surg.* 1995; 82:829–832.
- Todani T, Watanabe Y, Toki A, Morotomi Y. Classification of congenital biliary cystic disease: Special reference to type Ic and IVA cysts with primary ductal stricture, *Journal of Hepato-Biliary-Pancreatic Surgery.* 2003; 10(5):340-344
- Singham J, Yoshida EM, Scudamore CH. Choledochal cysts: part 1 of 3: Classification and pathogenesis *Can J Surg.* 2009; 52:434-440.
- Visser BC, Suh I, Way LW, Kang SM. Congenital choledochal cysts in adults *Arch Surg* 2004; 139:855-860.
- Pereira LH, Bustorff-Silva JM, Sbraggia-Neto L, Bittencourt DG, Hessel G. [Choledochal cyst: a 10-year experience] *J Pediatr (Rio J).* 2000; 76:143-148.
- Lee HC, Yeung CY, Fang SB, Jiang CB, Sheu JC *et al.* Biliary cysts in children--long-term follow-up in Taiwan *J Formos Med Assoc.* 2006; 105:118-124.
- Hewitt PM, Krige JE, Bomman PC, Terblanche J.

- Choledochal cysts in adults *Br J Surg.* 1995; 82:382-385.
28. Aguilera V, Rayón M, Pérez-Aguilar F, Berenguer J. Caroli's syndrome and imaging: report of a case *Rev Esp Enferm Dig.* 2004; 96:74-76.
  29. Kiresi DA, Karabacakoglu A, Dilsiz A, Karakose S. Spontaneous rupture of choledochal cyst presenting in childhood *Turk J Pediatr.* 2005; 147:283-286.
  30. Huang CS, Huang CC, Chen DF. Choledochal cysts: Differences between pediatric and adult patients, *Journal of Gastrointestinal Surgery.* 2010;14(7):1105-1110.  
DOI: 10.1007/s11605-010-1209-8 [Epub Apr 27, 2010]
  31. Oh SH, Chang SH, Kim HJ, Cho JM, Hwang JH, Namgoong JM, *et al.* Cholangiographic characteristics of common bile duct dilatation in children *World Journal of Gastroenterology.* 2015;21(20):6229-6235. DOI: 10.3748/wjg.v21.i20.6229
  32. Youn HS, Seo JH, Park CH, Cho JM, Park JJ. An infantile case of cholelithiasis initially misdiagnosed as choledochal cyst *Pediatrics International.* 2012; 54(1):168-169.
  33. Yamaguchi M. Congenital choledochal cyst. Analysis of 1,433 patients in the Japanese literature, *American Journal of Surgery.* 1980; 140(5):653-657.
  34. Yamoto M, Urushihara N, Fukumoto K, Miyano G, Nouse H, Morita K *et al.* Usefulness of laparoscopic cholecystostomy in children with complicated choledochal cyst *Asian Journal of Endoscopic Surgery.* 2015; 8(2):153-157.
  35. De Vries JS, de Vries S, Aronson DC, Bosman DK, Rauws EA, Bosma A *et al.* Choledochal cysts: Age of 20 presentation, symptoms, and late complications related to Todani's classification, *Journal of Pediatric Surgery.* 2002; 37(11):1568-1573.
  36. Diao M, Li L, Cheng W. Coagulopathy in a subtype of choledochal cyst and management strategy, *World Journal of Gastroenterology.* 2014; 20(30):10606-10612.
  37. Lam WW, Lam TP, Saing H, Chan FL, Chan KL. MR cholangiography and CT cholangiography of pediatric patients with choledochal cysts, *American Journal of Roentgenology.* 1999; 173(2):401-405.
  38. Drabek J, Keil R, Stovicek J, Lochmannova J, Hlava S, Snajdauf J *et al.* The role of endoscopic retrograde cholangiopancreatography in choledochal cysts and/or abnormal pancreatobiliary junction in children *Przegląd Gastroenterologiczny.* 2017; 12(4):303-309.
  39. Sacher VY, Davis JS, Sleeman D, Casillas J. Role of magnetic resonance cholangiopancreatography in diagnosing choledochal cysts: Case series and review. *World Journal of Radiology.* 2013; 5(8):304-312.
  40. Murphy AJ, Axt JR, Crapp SJ, Martin CA, Crane GL, Lovvorn HN 3rd. Concordance of imaging modalities and cost minimization in the diagnosis of pediatric choledochal cysts *Pediatric Surgery International.* 2012; 28(6): 615-621.
  41. Schaefer JF, Kirschner HJ, Lichy M, Schlemmer HP, Schick F, Claussen CD, *et al.* Highly resolved free-breathing magnetic resonance cholangiopancreatography in the diagnostic workup of pancreaticobiliary diseases in infants and young children — Initial experiences, *Journal of Pediatric Surgery.* 2006; 41(10):1645-1651.
  42. Moyer V, Freese DK, Whittington PF, Olson AD, Brewer F, Colletti RB *et al.* North American Society for Pediatric Gastroenterology, Hepatology and Nutrition. Guideline for the evaluation of cholestatic jaundice in infants: Recommendations of the North American Society for Pediatric Gastroenterology, Hepatology and Nutrition, *Journal of Pediatric Gastroenterology and Nutrition.* Aug. 2004; 39(2):115-128
  43. De Angelis P, Foschia F, Romeo E, Caldaro T, Rea F, di Abriola GF *et al.* Role of endoscopic retrograde cholangiopancreatography in diagnosis and management of congenital choledochal cysts: 28 pediatric cases, *Journal of Pediatric Surgery.* 2012; 47(5):885-888.
  44. Otto AK, Neal MD, Slivka AN, Kane TD. An appraisal of endoscopic retrograde cholangiopancreatography (ERCP) for pancreaticobiliary disease in children: Our institutional experience in 231 cases *Surgical Endoscopy.* 2011; 25(8):2536-2540.
  45. Hill SJ, Clifton MS, Derderian SC, Wulkan ML, Ricketts RR. Cystic biliary atresia: A wolf in sheep's clothing, *The American Surgeon.* 2013; 79(9):870-872.
  46. Gail E Besner MD. Chief Editor: Harsh Grewal, MD, FACS, FAAP. *Pediatric Choledochal Cyst Surgery Treatment & Management-Medscape Drugs & Diseases Updated: Mar 22, 2018.*
  47. Büyükyavuz I, Ekinci S, Ciftçi AO, Karnak I, Senocak ME, Tanyel FC *et al.* A retrospective study of choledochal cyst: Clinical presentation, diagnosis and treatment, *The Turkish Journal of Pediatrics.* 2003; 45(4):321-325.
  48. Stringer MD, Dhawan A, Davenport M, Mieli-Vergani G, Mowat AP, Howard ER. Choledochal cysts: Lessons from a 20 year experience, *Archives of Disease in Childhood.* 1995; 73(6):528-531.
  49. Lipsett PA, Pitt HA, Colombani PM *et al.* Choledochal cyst disease. A changing pattern of presentation *Ann Surg.* 1994; 220(5):644-52
  50. Kasai M, Asakura Y, Taira Y. Surgical treatment of choledochal cyst *Ann Surg.* 1970; 172(5):844-51.
  51. Chijiwa K, Tanaka M. Late complications after excisional operation in patients with choledochal cyst *J Am Coll Surg.* 1994; 179(2):139-44.
  52. Shimotakahara A, Yamataka A, Yanai T *et al.* Roux-en-Y hepaticojejunostomy or hepaticoduodenostomy for biliary reconstruction during the surgical treatment of choledochal cyst: which is better? *Pediatr Surg Int.* 2005; 21(1):5-7
  53. Le DM, Woo RK, Sylvester K, Krummel TM, Albanese CT. Laparoscopic resection of type 1 choledochal cysts in pediatric patients *Surgical Endoscopy.* 2006; 20(2):249-251.
  54. Wang B, Feng Q, Mao JX, Liu L, Wong KK. Early experience with laparoscopic excision of choledochal cyst in 41 children *J Ped Surg.* 2012; 47(12):2175-8.
  55. Liuming H, Hongwu Z, Gang L, Jun J, Wenying H, Wong KK *et al.* The effect of laparoscopic excision vs open excision in children with choledochal cyst: A midterm follow-up study *J Ped Surg.* 2011; 46(4):662-5.
  56. Liem NT, Pham HD, Vu HM. Is the laparoscopic operation as safe as open operation for choledochal cyst

- in children? *J Laparoendosc Adv Surg Tech A*. 2011; 21(4):367-70.
57. Chan KW, Lee KH, Tsui SY, Mou JW, Tam YH. Laparoscopic management of antenatally detected choledochal cyst: A 10-year review *Surg Endosc*. 2016; 12:5494-5499.
58. Li L, Feng W, Jing-Bo F *et al*. Laparoscopic-assisted total cyst excision of choledochal cyst and Roux-en-Y hepatoenterostomy *J Pediatr Surg*. 2004; 39(11):1663-6.
59. Diao M, Li L, Li Q, Ye M, Cheng W. Single-incision versus conventional laparoscopic cyst excision and Roux-Y hepaticojejunostomy for children with choledochal cysts: a case-control study *World J Surg*. 2013; 37(7):1707-13.
60. Diao M, Li L, Cheng W. Role of laparoscopy in treatment of choledochal cysts in children *Pediatr Surg Int*. 2013; 29(4):317-26.
61. Martinez-Ferro M, Esteves E, Laje P. Laparoscopic treatment of biliary atresia and choledochal cyst *Semin Pediatr Surg*. 2005; 14(4):206-15.
62. Cosentino CM, Luck SR, Raffensperger JG, Reynolds M. Choledochal duct cyst: resection with physiologic reconstruction. *Surgery discussion*. 1992; 112(4):740-7.
63. Reynolds M, Luck SR, Raffensperger JG. The valved conduit prevents ascending cholangitis: a follow-up *J Pediatr Surg*. 1985; 20(6):696-702.
64. Liu DC, Rodriguez JA, Meric F, Geiger JL. Laparoscopic excision of rare type II choledochal cyst: case report and review of the literature *J Pediatr Surg*. 2000; 35(7):1117-9.
65. Ouässi M, Kianmanesh R, Belghiti J, Ragot E, Mentha G, Adham M *et al*. Todani Type II Congenital Bile Duct Cyst: European Multicenter Study of the French Surgical Association and Literature Review *Ann Surg* 2015; 262(1):130-8.
66. Maning P, Polley T, Oldam K. Choledochoceles: An unusual form of choledochal cyst. *Pediatr Surg Int*. 1990 ; 5:22-6.
67. Ohi R, Yaoita S, Kamiyama T, *et al*. Surgical treatment of congenital dilatation of the bile duct with special reference to late complications after total excisional operation. *J Pediatr Surg*. 1990 Jun. 25(6):613-7.
68. Ohi R, Koike N, Matsumoto Y *et al*. Changes of intrahepatic bile duct dilatation after surgery for congenital dilatation of the bile duct. *J Pediatr Surg*. 1985 Apr. 20(2):138-42.
69. Todani T, Narusue M, Watanabe Y, *et al*. Management of congenital choledochal cyst with intrahepatic involvement. *Ann Surg*. 1978 Mar. 187(3):272-80.
70. Diao M, Li L, Cheng W. To drain or not to drain in Roux-en-Y hepaticojejunostomy for children with choledochal cysts in the laparoscopic era: A prospective randomized study *J Ped Surg*. 2012; 47(8):1485-9.
71. Patil V, Kanetkar V, Talpallikar MC. Hepaticoduodenostomy for biliary reconstruction after surgical resection of choledochal cyst: A 25-year experience, *Indian Journal of Surgery*. 2015; 77(Suppl 2):240-24.