



P-ISSN: 2664-3685  
E-ISSN: 2664-3693  
[www.paediatricjournal.com](http://www.paediatricjournal.com)  
IJPG 2022; 5(1): 41-44  
Received: 23-11-2021  
Accepted: 26-12-2021

**Dr. Jasmine Chandi**  
Senior Resident, Department  
of Paediatrics, MS Ramaiah  
Medical College, Bengaluru,  
Karnataka, India

**Dr. Karunakara BP**  
Professor, Department of  
Paediatrics, MS Ramaiah  
Medical College, Bengaluru,  
Karnataka, India

**Dr. Shruthi Patil**  
Associate Professor,  
Department of Paediatrics, MS  
Ramaiah Medical College,  
Bengaluru, Karnataka, India

**Dr. Somashekar AR**  
Professor and Head of  
Department, Department of  
Paediatrics, MS Ramaiah  
Medical College, Bengaluru,  
Karnataka, India

**Corresponding Author:**  
**Dr. Jasmine Chandi**  
Senior Resident, Department  
of Paediatrics, MS Ramaiah  
Medical College, Bengaluru,  
Karnataka, India

## A case report of Dyke-Davidoff-Mason syndrome, a rare cause of cerebral hemiatrophy: A rare condition

**Dr. Jasmine Chandi, Dr. Karunakara BP, Dr. Shruthi Patil and Dr. Somashekar AR**

DOI: <https://doi.org/10.33545/26643685.2022.v5.i1a.166>

### Abstract

**Background:** There is a lack of data on the prevalence of Dyke-Davidoff-Masson syndrome (DDMS), a rare neurological condition that has only been documented in case reports and series. The majority of those affected are children. Because of its rarity, many clinicians may misdiagnose or underreport this condition. DDMS was discovered on imaging in a patient who was initially misdiagnosed as having a young stroke of unknown aetiology.

**Keywords:** Neuropathic, anticonvulsant, paediatric

### Introduction

Atrophy or hypoplasia of one cerebral hemisphere (hemiatrophy) is referred to as Dyke-Davidoff-Masson syndrome (DDMS). This usually occurs as a result of an injury to the developing brain during the foetal or early childhood period.

Brain injury severity affects the specific symptoms a patient will experience. 1st Recurrent seizures<sup>[2, 3]</sup> facial asymmetry, contralateral hemiplegia, mental retardation or learning disability, and speech and language disorders are the most common symptoms that patients with this condition experience. Psychiatric manifestations such as schizophrenia have only been reported infrequently in the past<sup>[4, 5]</sup>. Radiological features include cerebral hemiatrophy and ipsilateral compensatory hypertrophy of the skull and sinuses, which are typical. Adolescents and adults were the primary populations affected by the syndrome. However, it can be found in children as well<sup>[6]</sup>.

### A case study

A 10-year-old boy with hemiparesis on the right side of his body was brought in for treatment of recurrent complex partial seizures. At the age of six, the patient began experiencing headaches. Doctors were called in after the patient's mother noticed that the patient had a right-sided weakness. Neither h/o trauma nor infection were present. Birth records were unremarkable, and there was no family history to speak of. The patient was not enrolled in any formal educational programmes. The child's cognitive abilities were severely impaired, and he was undernourished when he was examined. The results of the physical examination were normal. Right-sided UMN facial palsy, hemiparesis on the right side with power of 4/5, brisk reflexes, and reduced sensation were found during a central nervous system examination. Other systems were unremarkable in their examination. Anemia was detected at a moderate level after a complete blood count. Testing for kidney and liver function came back negative. Protein S, protein C, anti-thrombin III, anti-phospholipid antibody, anti-cardiolipin antibody, and lupus anticoagulant were all negative in the young stroke patient's workup. Dyke Davidoff Masson syndrome-like gliotic and encephalomalacic changes were seen on MRI in the left frontoparietotemporal lobes, as well as left cerebral hemiatrophy (Fig-1, 2). An abnormally small left middle cerebral artery was found in the brain scan results interpretations based on x-ray images fptce and ex vacuo left lateral ventricle dilatation are seen in conjunction with left cerebral hemisphere atrophy and frontoparietotemporal cystic encephalomatia additionally, the adjacent skull vault on the left side is thicker than it is on the right side.

**Discussion**

Dyke *et al.* [7] proposed the Dyke–Davidoff–Masson syndrome (DDMS) in 1933 as a group of nine patients with a variety of symptoms, including hemiparesis, seizures, facial asymmetry, and mental retardation.

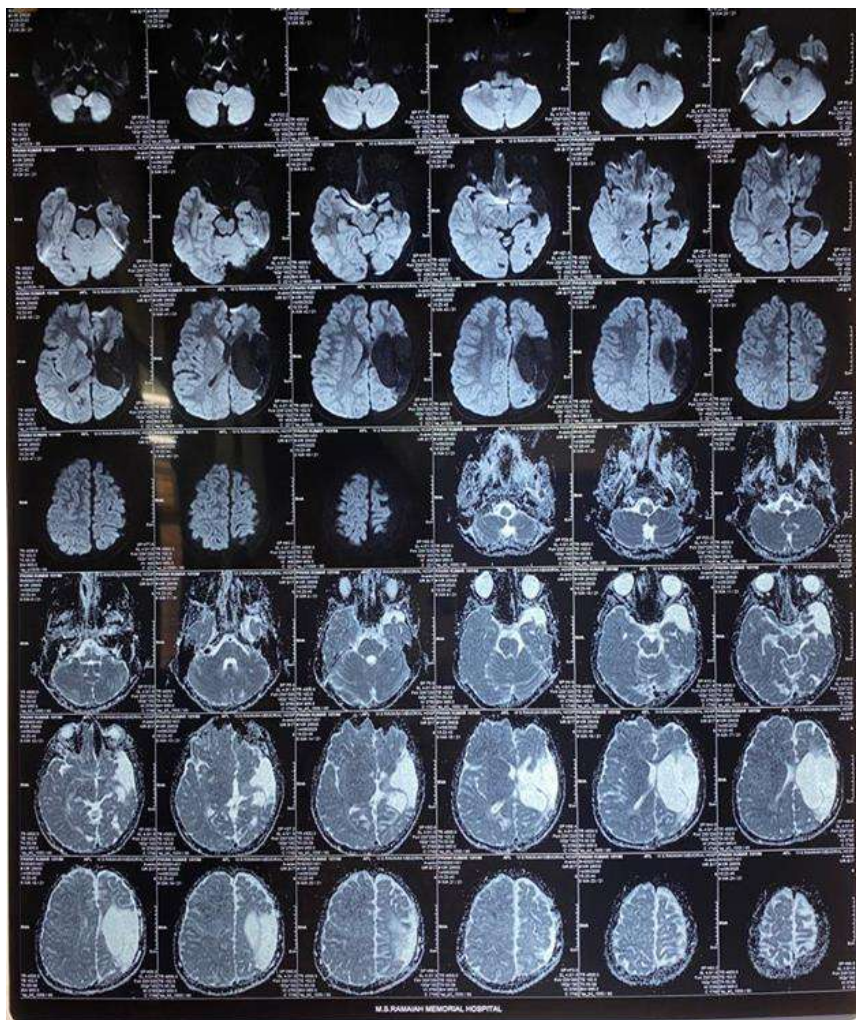
When a baby is born, it has half of its adult brain volume. It had reached three-quarters by the time he was three years old. Pregnancy hemispheres are still smooth and undisturbed until the beginning of the fourth month of the fourth month. All of the significant sulci have been identified by the end of the eighth month [8]. As the growing brain exerts pressure on the bony skull table, the size and shape of the head gradually increase. Increased width of diploic spaces, enlarged sinuses and elevated orbital roof are all symptoms of a brain that does not grow properly. Brain damage that occurs before the age of 3 can cause these changes. However, they may begin to appear as soon as 9 months after the injury [9].

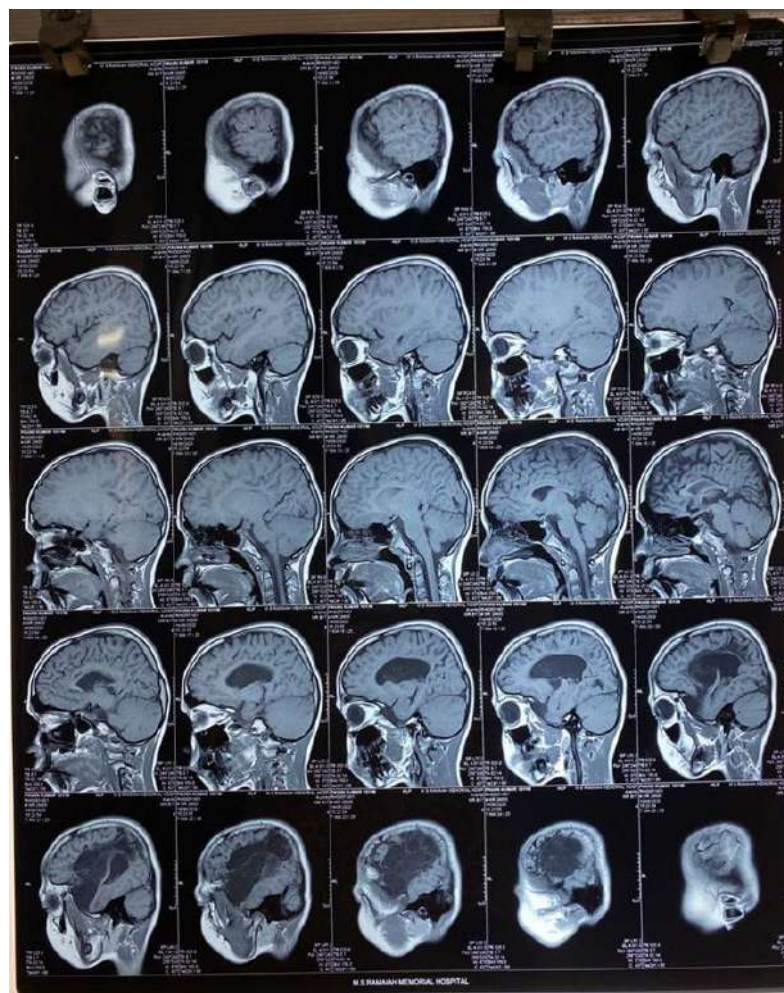
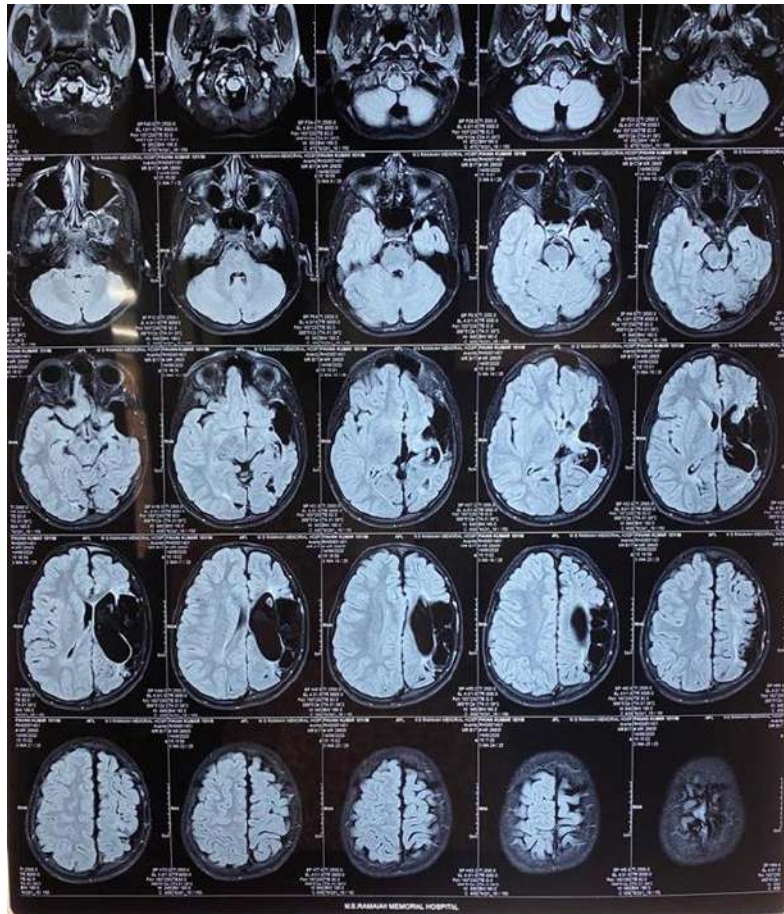
Asymmetries in the growth of the cerebral hemispheric hemispheres, as well as a midline shift that results in atrophy or hypoplasia on one side, are the hallmarks of this condition [10]. These include congenital abnormalities, cerebral infarction, vascular abnormalities, infections, and gestational vascular occlusion, mainly in the middle cerebral vascular territory. Prenatal causes include Post-natal causes include trauma, hypoxia, intracranial haemorrhage, tumours, infections, and prolonged febrile seizures. Reduced carotid artery blood flow from an aortic coarctation may also be to blame [11].

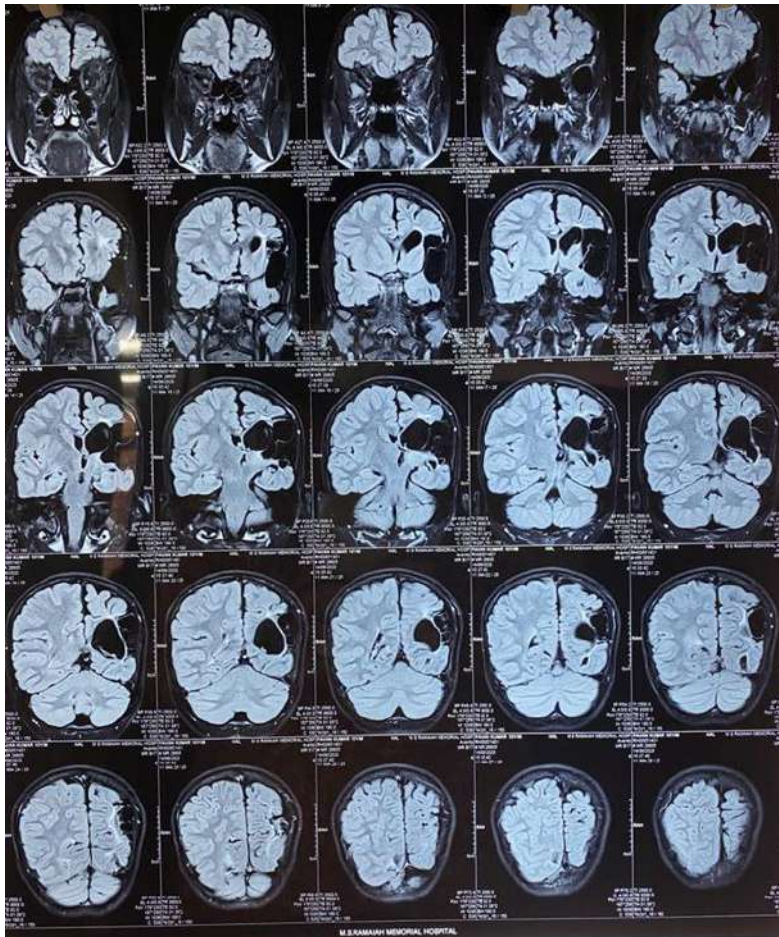
Congenital (infantile) DDMS and acquired DDMS are the

two main types. A shift in midline structures to the disease's side occurs in congenital hemiatrophy, and the sulcal prominence that would normally replace the gliotic tissue is missing. When compared to cerebral hemiatrophy, which occurs in early adulthood, this feature distinguishes it. Injury to the brain that occurs after birth or after sulcation ends will result in prominent sulcal spaces in the atrophied cerebral hemispheres [12].

It is important to treat DDMS patients with anticonvulsants in order to prevent seizures from occurring. Multiple anticonvulsants may be used at the same time. In our case, tablet carbamazepine 10 mg/kg/day, followed by 20 mg/kg/day of maintenance, was used as a starting point. Physiotherapy, occupational therapy, and speech therapy all play an important role in the long-term care of children with autism spectrum disorders (ASD). Hemispherectomies are effective in treating children with intractable and disabling epilepsy and hemiplegia, with an 85 percent success rate. Hemiparesis has a better prognosis if it appears after the age of two years and is not associated with prolonged or recurrent seizures. The diagnostic value of radio-imaging cannot be overstated. Unusual causes of intractable seizures should always be considered [13]. Rural neurologists and paediatricians have an important role to play in the diagnosis and treatment of hemispherectomy, which is not available even in many urban tertiary care centres. The treatment should focus on controlling seizures, revising drug doses from time to time, and providing at-home physiotherapy [14].







**Fig 1-4:** Radiographs showing atrophy of the left cerebral hemisphere with fronto parieto temporal cystic encephalomalacia and ex vacuo dilation of the left lateral ventricle. There is also relative thickening of the adjacent skull vault as compared to the right side.

#### References

1. Koshy B, Surendrababu NR. Dyke-Davidoff-Masson Syndrome. Singapore: Ann Acad Med. 2010;39:501-2.
2. Shetty DS, Lakhkar BN, John JR. Neurology India, 2003;51:136.
3. Dyke-Davidoff-Masson Syndrome, Narain NP, Kumar R, Narain B. Indian Pediatr. 2008;45:927-8.
4. Unal O, Tombul T, Cirak B, Anlar O, Incesu L, Kayan M. Left hemisphere and male sex dominance of cerebral hemiatrophy(DDMS) Clin Imaging. 2004;28:163-5.
5. Pendse NA, Bapna P, Menghani V, Diwan A. Dyke-Davidoff-Masson Syndrome. Indian J Pediatr. 2004;71:943.
6. In a DDMS case, temporo-spatial analysis defines epileptogenic and functional zones. Seizure. 2011;20:713-716.
7. Dyke CG, Davidoff LM, Masson CB. Cerebral hemiatrophy and homolateral hypertrophy of the skull and sinuses. Surg Gynecol Obstet. 1933;57:588-600.
8. Graham A, Molnar Z. Development of the Nervous System. In: Standring S, editor. Gray's Anatomy. 40th ed. London, Churchill Elsevier, Livingstone, 2008, p. 385.
9. Parker CE, Harris N, Mavalwala J. Dyke-Davidoff-Masson Syndrome: Five case studies and deductions from dermatoglyphics Pediatr Clin North Am. 1972;11:288-92.
10. Solomon GE, Hilal SK, Gold AP, Carter S. Natural history of acute hemiplegia in childhood. Brain. 1970;93:107-20.
11. Sener RN, Jinkins JR. Clin Imaging. 1992;16:93-7.
12. Stred SE, Byrum CJ, Bove EL, Oliphant M. Midaortic arch coarctation presenting with monoparesis Ann Thorac Surg. 42:210-12.
13. Degenerative diseases and hydrocephalus, Rao KC. In: Lee SH, Rao KC, Zimmerman RA, editors. Cranial MRI and CT. McGraw-Hill, New York, 1999, pp. 212-4.
14. Zilkha A. CT of Cerebral Hemiatrophy. Am J Roentgenol. 1980;135:259-62.