



INTERNATIONAL JOURNAL OF PAEDIATRICS AND GERIATRICS

P-ISSN: 2664-3685

E-ISSN: 2664-3693

www.paediatricjournal.com

IJPG 2021; 4(1): 28-30

Received: 12-12-2020

Accepted: 19-01-2021

Dr. Vishal Jain

Department of Pediatrics and Neonatology. Jaipur Golden Hospital, 2, Institutional Area, Sector-III, Rohini, Delhi, India

Dr. Anirudh Ghai

Department of Pediatrics and Neonatology. Jaipur Golden Hospital, 2, Institutional Area, Sector-III, Rohini, Delhi, India

Dr. Bhagyashree Mohapatra

Department of Pediatrics and Neonatology. Jaipur Golden Hospital, 2, Institutional Area, Sector-III, Rohini, Delhi, India

Dr. Shekhar Biswas

Department of Pediatrics and Neonatology. Jaipur Golden Hospital, 2, Institutional Area, Sector-III, Rohini, Delhi, India

Dr. Vipra Bhagat

Department of Pediatrics and Neonatology. Jaipur Golden Hospital, 2, Institutional Area, Sector-III, Rohini, Delhi, India

Corresponding Author:

Dr. Vishal Jain

Department of Pediatrics and Neonatology. Jaipur Golden Hospital, 2, Institutional Area, Sector-III, Rohini, Delhi, India

Case report of hepatic abscess with lung consolidation in a neonate: A rare entity

Dr. Vishal Jain, Dr. Anirudh Ghai, Dr. Bhagyashree Mohapatra, Dr. Shekhar Biswas and Dr. Vipra Bhagat

DOI: <https://doi.org/10.33545/26643685.2021.v4.i1a.126>

Abstract

Neonatal liver abscess is an uncommon finding and very few cases have been reported till date. A 36+5 week near term neonate presented with clinical symptoms of sepsis, convulsion on day 3 of life and hepatomegaly with history of birth asphyxia, chorioamnionitis and oligohydrominos. The baby was diagnosed with liver abscess with left lung consolidation by radiological investigations and the abscess was aspirated under Ultrasound-Guided and treated with antibiotics. The liver abscess resolved on follow up and the baby was discharge healthy.

Keywords: Hepatic abscess, neonate, consolidation

Introduction

Hepatic Abscess is a rare disorder in the neonatal period of life with high mortality and morbidity [6]. To the best of our knowledge till date around 100 neonates with hepatic abscess have been reported in literature [4]. Newborns with low gestational age, low birth weight, underwent invasive procedure, infection and on total parental nutrition are high risk candidates for hepatic abscess [1]. Hepatic abscess is uncommon in neonatal period of life and can be life threatening event if early interventions for treatment are not taken. Chorioamnionitis might be suggested as possible maternal risk factor in our case. The route of spread can be by ascending infection by umbilical venous catheterisation and portal vein, hematogenous spread by biliary tree and by direct contagious spread [2, 7]. Hepatic abscess can be solitary or multiple and can be associated with other organs such as spleen, brain and lungs [4]. Left lung consolidation was also associated with hepatic abscess in our case. We are reporting a case of hepatic abscess with lung involvement in a near term neonate with sepsis.

Case report

A female infant, 36+5 weeks was delivered by normal vaginal delivery with maternal history of premature rupture of membrane and oligohydrominous with birth weight of 2700 grams. The baby did not cry immediately after birth and received resuscitation. The baby was admitted in NICU and shifted to mother side of day 2 of life. On day 3 of life, the baby had one episode of abnormal body movement and decreased activity with respiratory distress hence the baby was referred to our side and admitted in NICU. The baby was started on oxygen supplementation by blender and a sepsis workup was done. The baby was made NPO and total parental nutrition was started. Intravenous antibiotics were started in view of positive sepsis screen. On day 9 of life, a ultrasound abdomen was done in view of hepatomegaly and it showed necrotic live abscess (figure 1). CECT abdomen was done on day 10 of life showed enlarged liver (Right lobe- 72mm in cranio-caudal extent). A bilobed shaped low attenuation measuring approximately 21mm (AP) *22mm (CC) *18mm (TR) in size with volume approximately 6cc was seen superior to gall bladder and extending posterior and inferior to gall bladder involving segments IV and V and reaching upto subcapsular location suggestive of Hepatic abscess. It appeared in continuation with another collection measuring approximately 32mm(AP)*22mm(CC) in size with volume approximately around 8mm in sub-hepatic region likely due to abscess rupture(figure 2a,2b). Thick walled cavity in left lower lobe of lung was suggestive of lung involvement. Pediatric surgeon opinion was taken and USG guided hepatic abscess aspiration was done. The sample collected was approximately around 4.5 ml and was frank pus and was sent for culture.

The culture reported no growth mostly due to usage of antibiotics. On day 20 of life a repeat USG abdomen was done and showed moderate regression in the size and

volume of the liver abscess and the lung fields were clear. In our case the cause of hepatic abscess can be mostly due to chorioamnionitis.

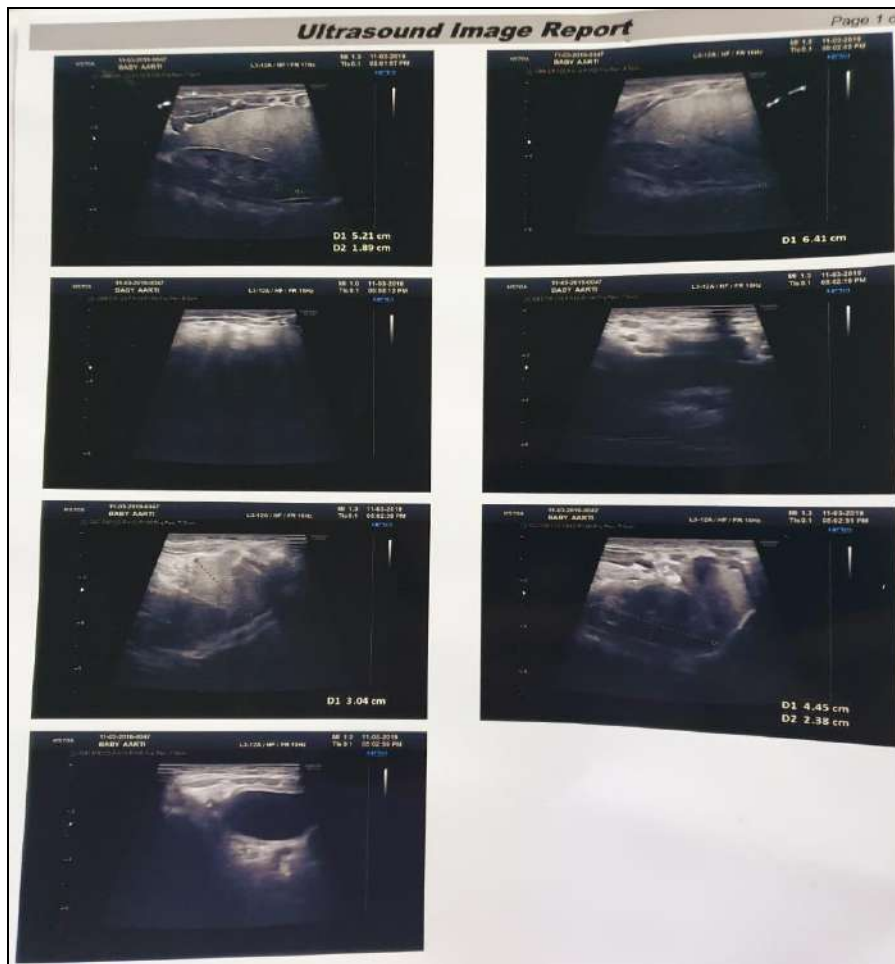

Fig 1: USG whole Abdomen showing hepatic abscess

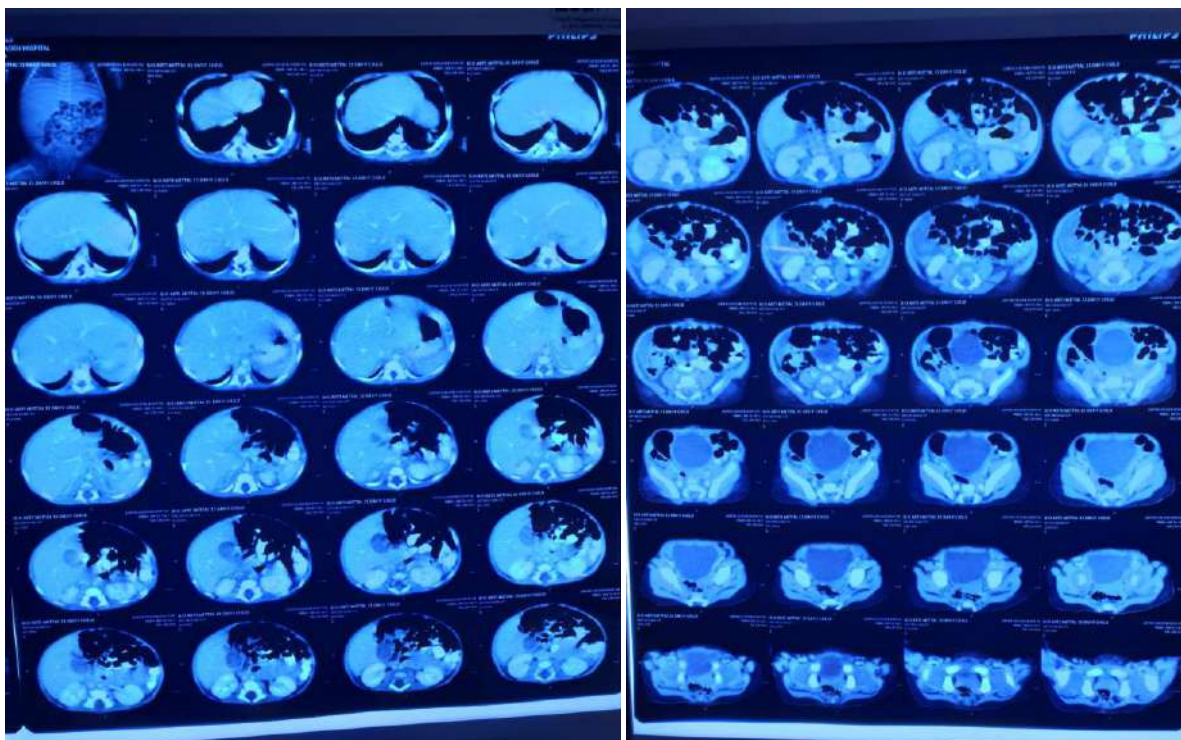


Fig 2 (a/b): CECT Images showing hepatic abscess

Discussion

In our case report the neonate had few of the high risk factors impending to hepatic abscess which were preterm, started on TPN and neonatal sepsis. Neonatal liver abscess are difficult to diagnosed and missed out due to its lesser incidence and symptoms. Neonatal sepsis with catheterization like umbilical and central lines, neonatal infection, TPN and prematurity are the most common predisposing factors [1, 7]. The most common organisms are *Staphylococcus Aureus*, *Streptococcus pyogenes*, *E Coli*, *Klebsiella*, *Pseudomonas*, *Corynebacterium acnes*, *anaerobes*, and *Candida albicans* isolated from solitary hepatic abscess in neonates [8, 1, 3, 5], but due to antibiotic coverage the culture reported no growth in our case. The combination of hepatomegaly, left lung consolidation and a positive sepsis screen in our case were the signs indicating for USG abdomen screening. Radiological modalities like abdominal ultrasonography, CT scan, and liver scan with technetium are helpful for diagnosis of hepatic abscess [9]. Ultrasound is the investigation of choice in pediatric patients for liver abscess and it can be used for monitoring the response as well as ultrasonic guidance of aspiration [10]. Abdominal US has been the first line investigation that can detect, locate, and define a liver abscess [4]. Portal vein thrombosis, portal cavernoma formation, and portal hypertension are known complications of neonatal liver abscess [4]. The treatment consists of correcting the predisposing factor (e.g., withdrawal of the umbilical catheter), percutaneous drainage with or without ultrasound guidance, or open drainage of the abscess affecting multiple lobes of the liver [5, 8]. The appropriate duration of treatment with antibiotics is not known till now, but it should be correlated clinically and with ultrasonography scans of the abscess and can give an idea about the regression of the size. But a minimum of 2 weeks of antibiotics coverage is necessary [11]. The treatment of neonatal liver abscess in our case was done by ultrasound guided aspiration and antibiotic coverage with follow up scans to assess the resolving of the abscess. Neonatal liver abscess can have good outcomes and minimal complications if the treatment modality is image guided aspiration or drainage with proper antibiotics coverage [8].

Acknowledgement

We would like to extent our gratitude to the staff of Department of pediatrics and Neonatology.

Authors Contribution

All the authors actively participated in the study work and approved the final manuscript.

Conflicts of Interest

The authors declare no conflicts of interest.

Reference

1. Tan NW, Sriram B, Tan-Kendrick AP, Rajadurai VS. Neonatal hepatic abscess in preterm Infants: A rare entity? *Ann Acad Med Singapore* 2005;34(9):558-564.
2. Semerci SY, Babayigit A, Cebeci B, Buyukkale G, Cetinkaya M. Hepatic Abscesses in Preterm Infants: Report of Three Cases and Review of the Literature. *J Trop Pediatr* 2016;62(3):255-260. doi:10.1093/tropej/fmv103
3. Sharma S, Mohta A, Sharma P. Hepatic abscess in a

- preterm neonate. *Indian Pediatr* 2007;44:226-8.
4. Sajjad Ur Rahman, Abid Ghalib, Muhammad Hasan Abdulghani, Abdullah Jan. Liver Abscess in a Term Baby: A Case Report and Review of Literature. *Dr. Sulaiman Al Habib Medical Journal*. 2019;2590-3349:1-1:27-29.
5. Singh AP, Gupta AK, Ansari M, Kumar SM. Neonatal liver abscesss with impending rupture presenting as abdominal wall swelling: A rare case. *J Clin Neonatol* 2017;6:270-2.
6. Bosnali O, Morahoğlu S, Cerrah Celayir A, Pektaş O. Liver abscess: increasing occurrence in premature newborns. *Journal of neonatal surgery* 2013;2(2):23.
7. Simeunovic E, Arnold M, Sidler D, Moore SW. Liver abscess in neonates, *Pediatr Surg Int* 2009;25:153-6.
8. Lee SH, Tomlinson C, Temple M, Amaral J, Connolly BL. Imaging-guided percutaneous needle aspiration or catheter drainage of neonatal liver abscesses: 14-year experience. *AJR Am J Roentgenol* 2008;190:616-22.
9. Anand S, Chanchlani R, Gupta V, Goyal S, Tiwari A. Hepatic Abscess in Preterm Newborn- A rare entity. *Int J Med Res Rev* 2014;2(2):169-171. doi:10.17511/ijmrr.2014.i02.020
10. Moss TJ, Pysker TJ. Hepatic abscess in neonates. *Am J Dis child* 1981;135:726-728.
11. DeFranco P, Shook L, Goebel J, *et al.* Solitary Hepatic Abscess with Associated Glomerulonephritis in a Neonate. *J Perinatol* 2000;20:384-386.